

Application of Convolutional Neural Networks for Glands Instance Segmentation in the Images of Colon Epithelial Neoplasms

Ilya Mikhailov, Alexander Khvostikov, Andrey Krylov, Nina Oleynikova,
Pavel Malkov, Olga Kharlova, Natalya Danilova


Lomonosov Moscow State University, Moscow, Russia



Background & objectives

- a. Automatic segmentation of the mucous glands in histological images is an important step towards creating working diagnostic algorithms in digestive pathology.
- b. Changes in the gland shape and internal structure of the mucous glands are observed in both tumor and non-tumor diseases.
- c. Convolutional neural networks (CNN) are common algorithm for glands segmentation. However, existing CNN algorithms are trained and tested mainly on histological images of the normal structure mucosa of the colon.
- d. There is no data on the effectiveness of these algorithms on glands with the expansion and branching of crypts, on glands with low and high grade dysplasia.

Datasets

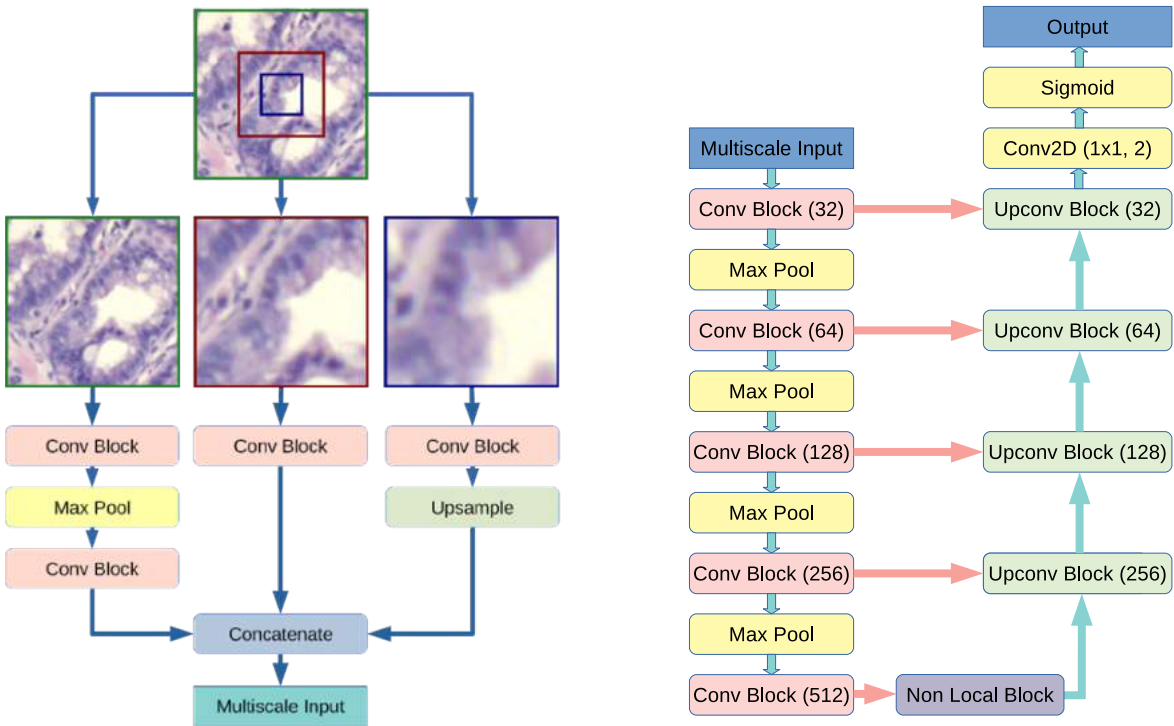
	PATH-DT-MSU dataset 20 images
The public Warwick-QU dataset	Material: paraffin sections (colon biopsy) Staining: hematoxylin and eosin Magnification: x100 Photo: Leica DM4000B/DFC495
165 images	
	http://imaging.cs.msu.ru/en/research/histology/path-dt-msu

Type of colon polyp	ICD-O code	Number
Hyperplastic polyp (HP)	N/A	13
Sessile serrated adenoma / Polyp (SSA/P)	8213/0	6
Normal structure	N/A	1
TOTAL		20

Methods

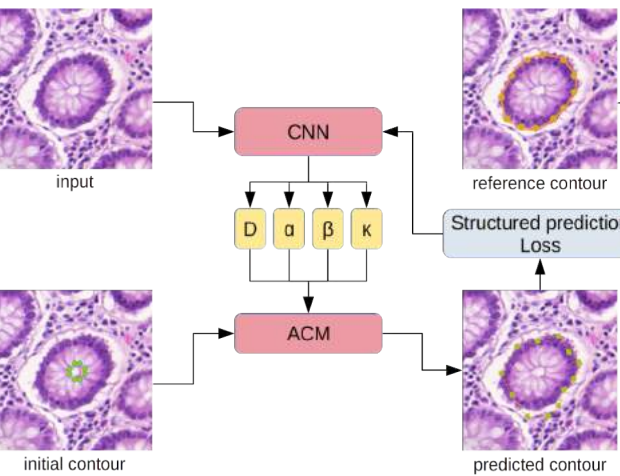
1. Automatic CNN-based Glands Segmentation

The main distinctive ideas of the proposed CNN lay in the multiscale architecture, using non-local blocks to capture long-range dependencies in the image and using a contour-aware loss function.



2. Trainable Active Contour Model

To perform instance segmentation of glands we propose a hybrid algorithm based on trainable active contour model. It uses a CNN to predict the energy fields which are then used by mathematical active contour model. This allows to tune the method to the branched glands segmentation task and perform accurate segmentation.

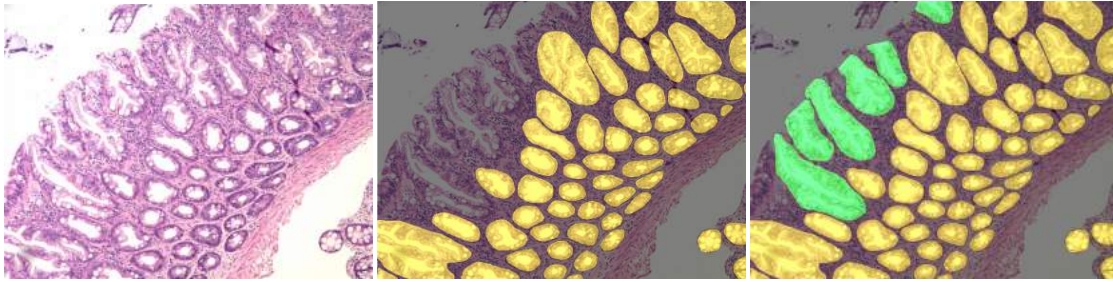


Postprocessing Algorithm

Due to the fact that the segmentation of each individual gland with the active contour model may not be ideal, in some areas of the image the resulting contours of several glands may overlap. This effect is obviously a segmentation error. To prevent the possibility of contour overlapping we propose a simple but at the same time effective postprocessing collision resolution algorithm.

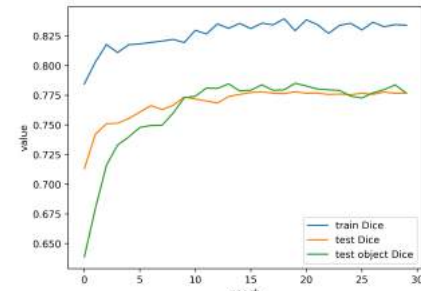
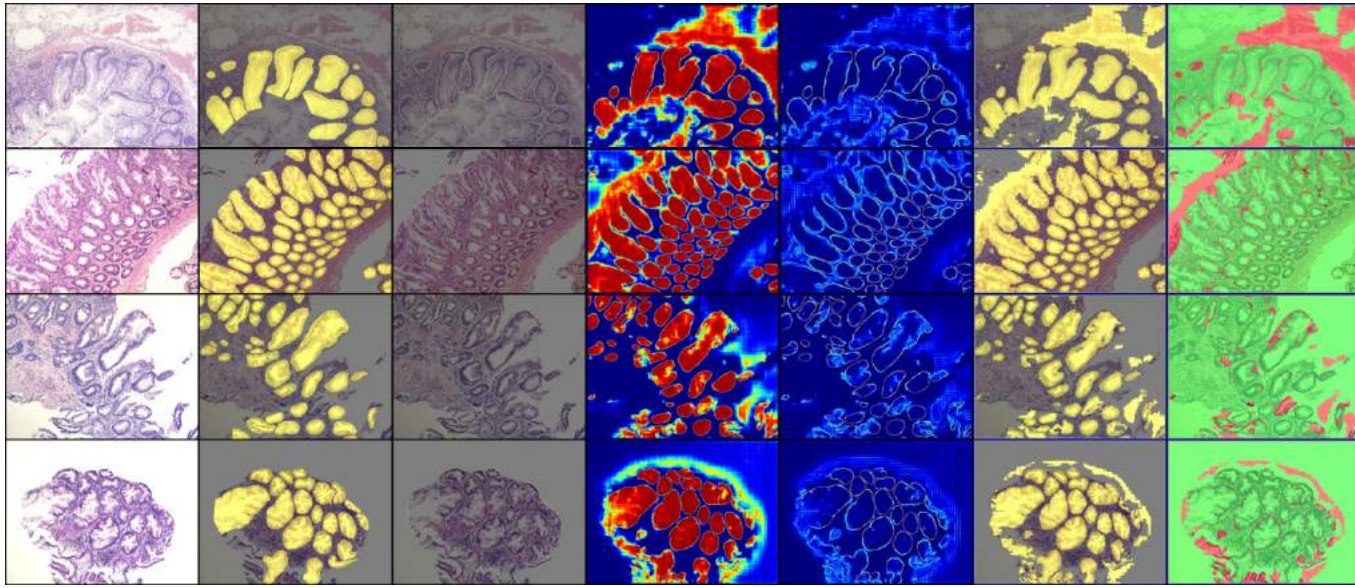
Results

Images Annotation with “Open” Glands in PATH-DT-MSU

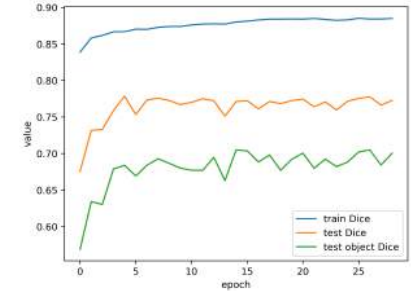


“Open” glands represent typical mucous glands built from goblet cells and enterocytes with open contour on histological images which are essentially the upper portions of the crypts. The “open” glands lack a number of cell nuclei on one side of the gland contour. Cell nuclei are an important feature for determining the gland contour in an image.

Visualization of CNN-based segmentation



Dice and object Dice scores while training on PATH-DT-MSU with normal glands annotations only

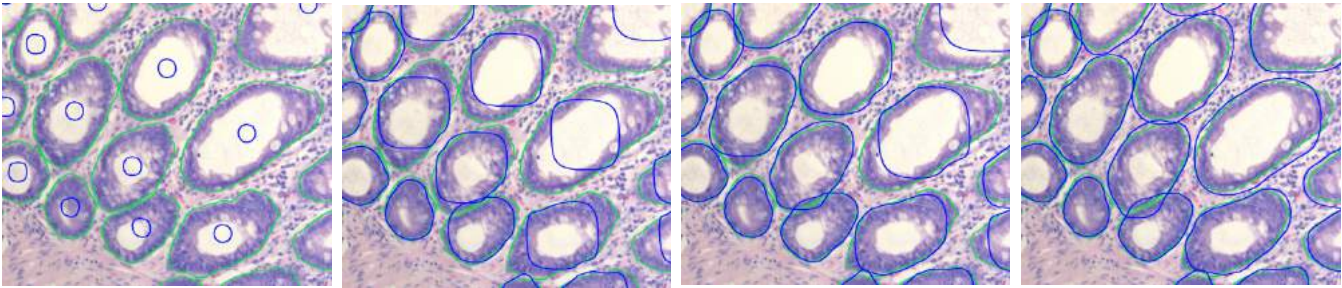


Dice and object Dice scores while training on PATH-DT-MSU with both normal and “open” glands annotations

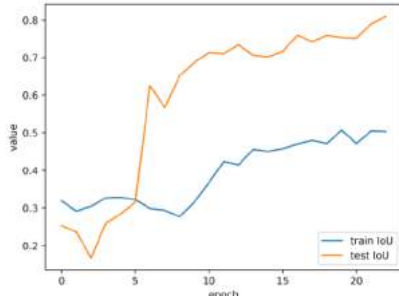
Warwick-QU dataset
Dice coefficient = 0.87

PATH-DT-MSU dataset
Dice coefficient = 0.78

Trainable Active Contour Model and Postprocessing Results



The ground-truth contours of glands are green, the predicted contour is blue. There are the states of contours at iteration 1, 20, 30 and 40.



Training a hybrid trainable active contour model: shows IoU (intersection over union) over epoch for training and test data

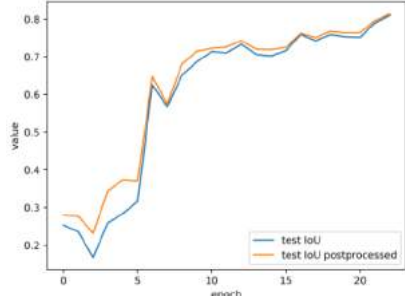


Fig. Shows IoU over epoch for test data with and without the use of a collision resolution algorithm

Conclusions

- A. We collected PATH-DT-MSU dataset that includes histological images of real biopsy / surgical material of colon epithelial neoplasms. PATH-DT-MSU is in active development and extension now.
- B. We propose a new CNN architecture for semantic segmentation of mucous glands in histological images of colon epithelial neoplasms that performs multiscale analysis and takes into account glands' contours.
- C. We present a hybrid segmentation method based on the trainable active contour model, which allows to perform instance gland segmentation.

Conflict of interests, Disclosures and Acknowledgments

We hereby declare that we had no business or personal interest. We have no conflict of interests. Development of mathematical algorithms was supported by Russian Science Foundation grant 17-11-01279.